

# Biomodulation of Osteoarthritis

By Martin Plotkin, MD, and Alta A. Smit, MD

## Introduction

Osteoarthritis (OA) is a chronic, disabling condition that affects synovial joints. Its pathogenesis involves multiple etiologies, including mechanical, genetic, and biochemical factors. OA is generally described as “noninflammatory” arthritis in contrast to rheumatoid arthritis, but this is increasingly recognized as a misnomer, since inflammation does indeed contribute to both the symptoms and the progression of OA.<sup>1</sup> Morning or inactivity stiffness is a common symptom in OA, but acute inflammatory flares with all the clinical signs (redness, warmth, swelling, and further loss of function) are also common in OA patients.

Figure 1: Degradation and repair in the matrix. In osteoarthritis, the catabolic/anabolic rhythm is disturbed.

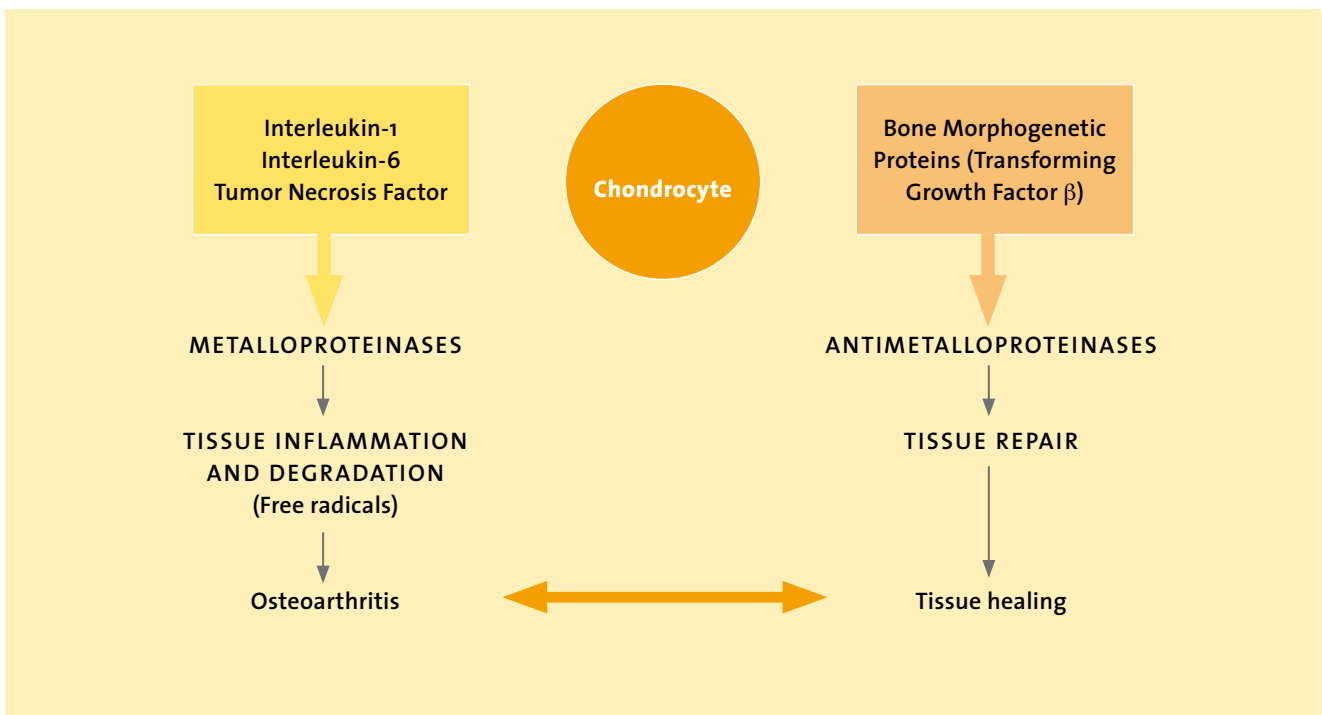
From the homotoxicological perspective, OA falls into the degeneration phase on the Disease Evolution Table and shares many of the characteristics of degenerative disease processes, namely, chronic inflammation accompanied by the release of dangerous free radicals such as peroxynitrite, disturbance of the normal cycle of degeneration and repair, and disturbance of angiogenic balance in the direction of inappropriate vascularization.

## Inflammation in osteoarthritis

The effects of subclinical chronic inflammation in OA are now increasingly being recognized.<sup>2</sup> The onset of acute inflammation is generally sudden, with the above-mentioned symptoms developing in a matter of minutes or hours. Neutrophils are

the most abundant cells and proinflammatory cytokines such as IL-1, TNF- $\alpha$ , and IL-8 are the most prominent. In contrast, chronic inflammation develops over a longer period of time and may persist for weeks, months, or years. Markers of chronic inflammation such as C-reactive protein (CRP) may be elevated in patients with OA and may be mediated by IL-6, which is the major cytokine secreted by macrophages. IL-6 may also play a role in angiogenesis, which is another factor contributing to the pathology of OA (see below).

The outcome of acute inflammation is elimination of the irritation, followed by restoration of the tissues to their original state. In chronic inflammation, on the other hand, inflammation and repair occur concurrently, and the joints remain



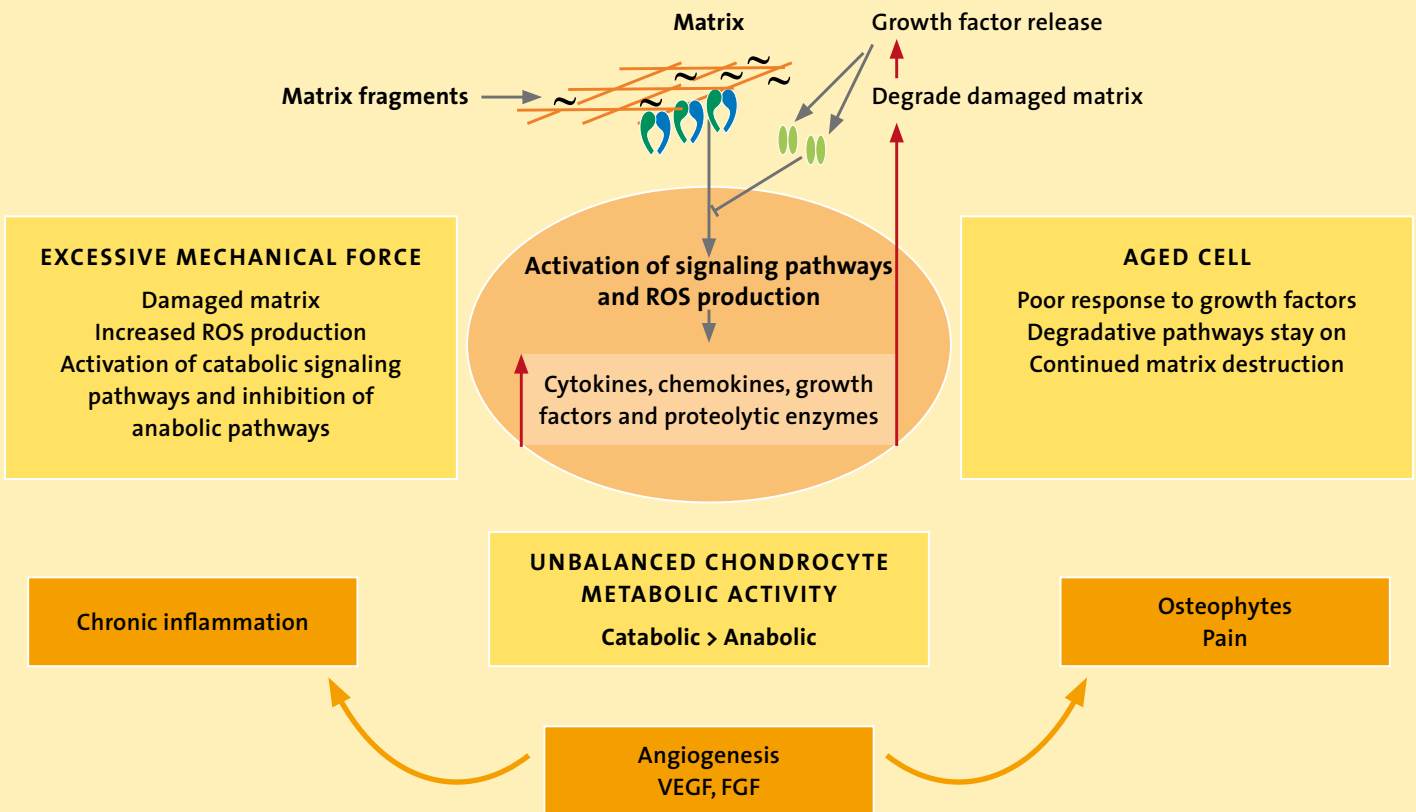


Figure 2: Molecular pathophysiology of osteoarthritis (adapted from Loeser<sup>1</sup>)

abnormal even after the inflammation subsides. In chronic inflammation, the cells that predominate are macrophages and often lymphocytic infiltrates. Chronic inflammation can therefore be seen as a misguided attempt on the part of chondrocytes and other cells to eliminate damaged tissue and to effect repair.

### Anabolic/catabolic imbalance

Oscillation between degradation and repair is a normal occurrence in the matrix. Although the extracellular matrix is the functional unit in this process, homeostasis is affected by chondrocytes. Matrix metalloproteinases (MMPs) are stimulated by inflammatory cytokines and matrix degradation products to induce degradation of older or damaged tissues and are counterbalanced by a number of growth factors, notably also members of the TGF- $\beta$  family, Bone Morphogenetic Proteins

(BMPs), which reciprocally inhibit the actions of the MMPs and therefore induce tissue healing. This catabolic/anabolic oscillation is of vital importance in normal tissue integrity.<sup>3,4</sup> When the process is disturbed (due to continuous tissue damage, either by mechanical stressors or toxins) or the body's ability to trigger repair reduced (due to either a deficiency of growth factors or an inability to respond to them, as is seen in old age), an overactive catabolic/anabolic cycle results (see Figure 1).

To better understand cartilage destruction, at least inasmuch as it is mediated by chondrocytes themselves (sometimes called chondrocytic chondrolysis), we must study the molecular mechanisms that disrupt the balance between chondrocyte catabolic and anabolic activity. Since chondrocytes are lost to cell death at some point in the process of cartilage destruction, it is also im-

portant to know whether these molecular factors also contribute to cell death.

The cause of chronic synovitis in OA is not well understood. Debris or parts of cartilage may be found in the synovium, where they provoke typical responses to foreign bodies. Mechanical injury can also lead to the secretion of free radicals or reactive oxygen species (ROS).

### ROS and chronic cartilage destruction

The role of ROS in cartilage damage remains controversial. Recently, Green et al. added to the literature describing the role of ROS release after mechanical injury in the progression of cartilage destruction.<sup>5</sup> Nitric oxide in particular is implicated in this process and may combine with other ROS to form the highly toxic compound peroxynitrite.

ROS also will induce inflammatory mediators, such as NF- $\kappa$ B, IL-1, and IL-6. ROS have been implicated in chondrocyte senescence.<sup>6</sup> ROS may also have a direct influence on the production of Vascular Endothelial Growth Factor (VEGF), a powerful stimulator of angiogenesis and chronic inflammation.<sup>7</sup>

### **Angiogenesis and chronic inflammation**

The formation of new blood vessels is essential during fetal development but rarely occurs in adults except in overzealous attempts at remodeling and regeneration, as in OA. Inflammatory mediators can stimulate angiogenesis either directly or indirectly. Inflammatory cells that produce this effect include macrophages and mast cells, which are present in the OA synovium. Macrophages are generally found wherever abnormal angiogenesis occurs, as in synovitis and tumors. Angiogenesis may be important in potentiating or perpetuating inflammation, rather than initiating it. On the other hand, angiogenesis may be indirectly self-perpetuating because it increases inflammatory cell infiltration and thus increases the cells that secrete angiogenic factors such as VEGF and Fibroblast Growth Factor (FGF-1).<sup>8</sup>

Vascularization of normally avascular cartilage and at the osteochondral junction is a feature of OA. In growing individuals, angiogenesis is required for normal endochondral ossification to close long bones. This process is mediated by VEGF from hypertrophic chondrocytes. In OA, however, growth through osteophytes at the joint margin also occurs through osteochondral ossification. Cartilaginous extensions of the articular surface become invaded by blood vessels, and bone extends from the subchondral structures.

Neoinnervation also follows angiogenesis and may contribute to pain in chronic synovitis (see Figure 2).

Targeting these aspects could lead to novel approaches to treating OA. The fact that Zeel, a homeopathic combination medication, is formulated to address these aspects, along with its excellent tolerability, makes it an ideal option for treating the chronic inflammation seen in OA.

### **Bioregulatory treatment of OA**

We have seen in the previous section that OA is characterized by chronic, low grade inflammation with frequent flare-ups of acute inflammation. Conventional treatments (NSAIDs, paracetamol/acetaminophen, and/or intra-articular corticosteroids) act to suppress only certain aspects of the inflammation and have significant side effects.

Intra-articular administration of hyaluronic acid attempts to supply the cartilage with proteoglycan support.<sup>9</sup> Combinations of chondroitin sulfate and glucosamine have long been used for this purpose in treating OA, with variable evidence of efficacy.<sup>10,11,12</sup> Some promising new treatments use autologous serum.<sup>13</sup> The use of antioxidants in OA has not been proven to be beneficial and remains controversial.<sup>14</sup>

In view of the pathogenesis outlined above, the use of low-concentration antigens with a multi-target regulation such as is seen in the antihomotoxic repertoire becomes interesting.

### **Traumeel and Zeel as combination therapy in OA**

Traumeel has been shown in studies to be both clinically efficacious and an immune-modulating medication<sup>15-21</sup> and should be considered for its immune-regulating properties, which promote repair while

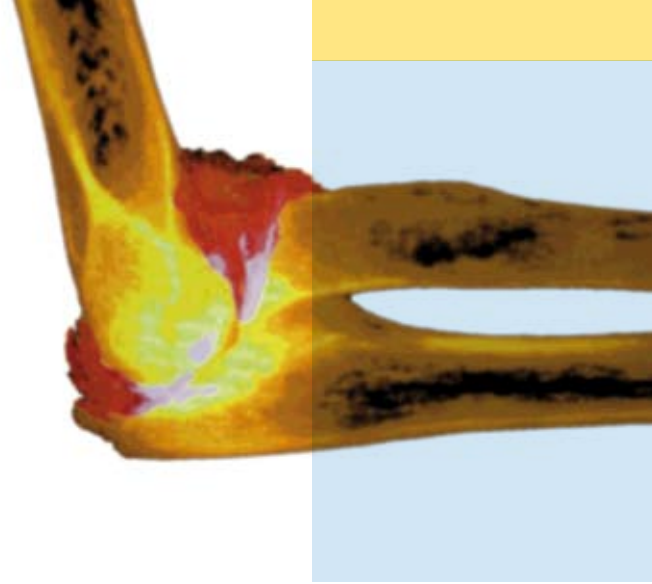
permitting a certain level of inflammation so that degradation of debris can occur.

Zeel has been used for degenerative arthritis for many years; empirical evidence indicates that it is as effective as Cox-1 and Cox-2 inhibitors in treating OA.<sup>22</sup> However, it may have a special role to play with regard to the pathophysiology of chronic inflammation. Many of its ingredients, such as Rhus tox, contain flavonoids, known for their antioxidant effects.<sup>23</sup> Rhus tox and Arnica also have been shown to have effects on IL-6, which is secreted by macrophages and may play a central role in chronic inflammation and angiogenesis. In an animal study, Stančíková demonstrated that when rabbits with experimentally induced arthritis were treated with either Zeel or a solvent (reference substance), the Zeel group developed far fewer erosions and less hypertrophic cartilage than the solvent group.<sup>24</sup> Histochemical analysis also revealed significant vascularization of the deeper layers of cartilage in the animals treated with the solvent, whereas the Zeel group developed only a few capillaries. (In view of the central role that angiogenesis appears to play in the pathophysiology of OA, this is a very important finding.) And finally, the arrangement of chondrocytes was also much more structured in the verum group. It is interesting to note that the alkaloid sanguinarine, found in *Sanguinaria canadensis* (one of Zeel's ingredients), has been shown to inhibit VEGF.<sup>25,26</sup>

### **Conclusion**

Ongoing research is clarifying the complex pathophysiology of OA. Disruption of the catabolic/anabolic cycle of the cartilaginous matrix appears paramount. New evidence

Osteoarthritis is generally described as “non-inflammatory” arthritis, but acute flare-ups with clinical signs of inflammation such as redness, warmth, swelling, pain, and loss of function are common in OA patients (here: inflamed elbow joint).



suggests that both the generation of ROS (through mechanical pressure) and angiogenesis contribute significantly to the development of chronic inflammation, tissue destruction, and pain. Standard treatment with NSAIDs aims primarily to reduce inflammation and control pain. Substances that inhibit MMPs are currently deemed too toxic to be of any use in OA. Viscosupplements, chondroitin sulfate and glucosamine, and some other novel treatments are also used, with variable evidence of efficacy.

Due to the different effects of the two antihomotoxic medications Traumeel and Zeel on acute and chronic inflammation, it is feasible to administer these two products in combination: Zeel for long-term treatment, Traumeel at the beginning of treatment and for acute flare-ups. Both of these medications have been shown to have excellent tolerability profiles. Further research is warranted to clarify the exact effect of Zeel on angiogenesis and the effect of the medication on ROS in chronic inflammation. ■

#### References

- Loeser RF. Molecular mechanisms of cartilage destruction: mechanics, inflammatory mediators, and aging collide. *Arthritis Rheum* 2006;54(5):1357-1360.
- Bonnet CS, Walsh DA. Osteoarthritis, angiogenesis and inflammation. *Rheumatology* 2005;44:7-16.
- Aigner T, Soeder S, Haag J. IL-1 $\beta$  and BMPs – interactive players of cartilage matrix degradation and regeneration. *Eur Cell Mater* 2006;12:49-56.
- Yasuda T, Poole AR. A fibronectin fragment induces type II collagen degradation by collagenase through an interleukin-1-mediated pathway. *Arthritis Rheum* 2002;46:138-148.
- Green DM, Noble PC, Ahuero JS, Birdsall HH. Cellular events leading to chondrocyte death after cartilage impact injury. *Arthritis Rheum* 2006;54:1509-1517.
- Yudoh K, Nguyen T, Nakamura H, Hongo-Masuko K, Kato T, Nishioka K. Potential involvement of oxidative stress in cartilage senescence and development of osteoarthritis: oxidative stress induces chondrocyte telomere instability and downregulation of chondrocyte function. *Arthritis Res Ther* 2005;7(2):R380-R391.
- Fay J, Varoga D, Wruck CJ, Kurz B, Goldring MB, Pufe T. Reactive oxygen species induce expression of vascular endothelial growth factor in chondrocytes and human articular cartilage explants. *Arthritis Res Ther* 2006;8(6):R189.
- Mentlein R, Pufe T. New functions of angiogenic peptides in osteoarthritic cartilage. *Curr Rheumatol Rev* 2005;1:37-43.
- Bellamy N, Campbell J, Robinson V, Gee T, Bourne R, Wells G. Viscosupplementation for the treatment of osteoarthritis of the knee. *Cochrane Database Syst Rev* 2006;19(2):CD005321.
- Barnhill JG, Fye CL, Williams DW, Reda DJ, Harris CL, Clegg DO. Chondroitin product selection for the glucosamine/chondroitin arthritis intervention trial. *J Am Pharm Assoc* 2006;46(1):14-24.
- Clegg DO, Reda DJ, Harris CL, et al. Glucosamine, chondroitin sulfate, and the two in combination for painful knee osteoarthritis. *N Engl J Med* 2006;354(8):795-808.
- Hochberg MC. Nutritional supplements for knee osteoarthritis – still no resolution. *N Engl J Med* 2006;354:858-859.
- Wehling P, Moser C, Frisbie D, et al. Autologous conditioned serum in the treatment of orthopedic diseases: the orthokine therapy. *BioDrugs* 2007;21(5):323-332.
- Henrotin Y, Kurz B. Antioxidant to treat osteoarthritis: dream or reality? *Curr Drug Targets* 2007;8(2):347-357.
- Heine H, Schmolz M. Induction of the immunological bystander reaction by plant extracts. *Biomed Ther* 1998;16(3):224-226.
- Porozov S, Cahalon L, Weiser M, Branski D, Lider O, Oberbaum M. Inhibition of IL-1 $\beta$  and TNF- $\alpha$  secretion from resting and activated human immunocytes by the homeopathic medication Traumeel® S. *Clin Dev Immunol* 2004;11(2):143-149.
- Lyss G, Knorre A, Schmidt TJ, Pahl HL, Merfort I. The anti-inflammatory sesquiterpene lactone helenalin inhibits the transcription factor NF-kappaB by directly targeting p65. *J Biol Chem* 1998;273(50):33508-33516.
- Zell J, Connert W-D, Mau J et al. Treatment of acute sprains of the ankle. *Biol Ther* 1989;7(1):1-6.
- Schneider C, Klein P, Stolt P, Oberbaum M. A homeopathic ointment preparation compared with 1% diclofenac gel for acute symptomatic treatment of tendinopathy. *Explore* 2005;1(6):446-452.
- Birnesser H, Oberbaum M, Klein P, Weiser M. The homeopathic preparation Traumeel S compared with NSAIDs for symptomatic treatment of epicondylitis. *J Musculoskelet Res* 2004;8(2-3):119-128.
- Singer SR, Amit-Kohn M, Weiss S, Rosenblum J, Lukaszewicz E, Itzhaki M, Oberbaum M. Efficacy of a homeopathic preparation in control of post-operative pain – A pilot clinical trial. *Acute Pain* 2007;9(1):7-12.
- Birnesser H, Stolt P. The homeopathic antiarthritic preparation Zeel comp. N: a review of molecular and clinical data. *Explore* 2007;3(1):16-22.
- Mersch-Sundermann V, Kassie F, Böhmer S, et al. Extract of Toxicodendron quercifolium caused genotoxicity and antigenotoxicity in bone marrow cells of CD1 mice. *Food Chem Toxicol* 2004;42(10):1611-1617.
- Stančíková M, Bély M, Metelmann HW, et al. Effects of Zeel comp. on experimental osteoarthritis in rabbit knee. *Rheumatologia* 1999;13:101-108.
- Basini G, Bussolati S, Santini SE, Grasselli F. Sanguinarine inhibits VEGF-induced angiogenesis in a fibrin gel matrix. *Biofactors* 2007;29(1):11-18.
- Basini G, Santini SE, Bussolati S, Grasselli F. Sanguinarine inhibits VEGF-induced Akt phosphorylation. *Ann N Y Acad Sci* 2007;1095:371-376.