

EXPERIMENTAL TREATMENT OF CHEMOTHERAPY - INDUCED STOMATITIS USING A HOMEOPATHIC COMPLEX PREPARATION: A PRELIMINARY STUDY

Menachem Oberbaum, M.D. • Reprinted from Biomedical Therapy • vol. XVI, No. 4, 1998, pp. 261-265

ABSTRACT

Stomatitis, by definition, is any form of inflammation or ulceration of the oral mucosa. The knowledge that chemotherapy often causes stomatitis may prevent the physician from planning such treatment because chemoradiotherapy is both toxic¹ and immunosuppressive². The pain and discomfort accompanying stomatitis can exacerbate the malnutrition due to anorexia or malabsorption. When stomatitis is complicated by a secondary infection, life-threatening sepsis may ensue.

Keywords: Chemotherapy, stomatitis, Traumeel®

INTRODUCTION

In general, the higher the mitotic index for malignant cells, the greater the effect of the cytotoxic agent. This applies not only to cancer cells but also to normal, rapidly-dividing cells, such as bone marrow cells and mucosal cells. Therefore, as in malignant cells, cycle-specific drugs damage the bone marrow and the mucosa. In patients receiving continuous infusions or in those with renal insufficiency, for example, methotrexate can cause severe mucositis. Fluorouracil causes stomatitis when given in high, aggressive doses or when administered via intra-arterial infusion. Other drugs which cause stomatitis are dactinomycin, cytarabine, doxorubicin, daunorubicin, and bleomycin. Stomatitis often develops following the administration of protocols containing TBI (total body irradiation), busulfan, VP16, or thiotepa (Table 1).

As can be expected, the myelosuppressive and stomatogenic effects of many drugs are similar and overlap, and when combined, one drug can augment the adverse side effects of the other. The greatest danger from damage to the oral mucosa and the mucosa lining the alimentary canal is the loss of the mechanical barrier to the entry of bacteria. When combined with granulocytopenia, the absence of this barrier is an important causal factor for suppressed defense mechanisms and malnutrition. Besides causing discomfort, large particles of necrotic mucosa that are exposed to bacterial infection during a bout of granulo-

cytopenia can serve as a *resistentiae-locus minoris*, thereby allowing bacteria and fungi to invade the body and multiply. For example, among patients who are hospitalized for treatment of acute leukemia or chronic leukemia in the blast stage, 33% develop oral infections, with about half caused by *Candida albicans*³, and 15% caused by the herpes simplex virus.⁴

Additionally, 10% of patients with non-hematologic carcinoma and less aggressive treatment reportedly developed oral infections.⁵ Broad-spectrum antibiotic treatment for infection is not without danger because antimicrobial agents also destroy the normal flora, allowing other pathogens to intrude. Systemic fungal infection is one of the main causes of post-bone marrow transplantation morbidity and mortality. Immunosuppressed patients with fungal infections in the mouth or conjunctiva or both, develop systemic infections. Clearly, the risk for developing systemic infections and the accompanying mortality can be decreased by preventing oral infections. Almost 40% of adults and about 90% of children receiving anticancer chemotherapy suffer from mucositis of the oral cavity,^{3,4} with the higher rate in children resulting from the especially intensive chemotherapy in this patient population. Bone marrow suppression alone can exacerbate such chronic oral problems as gingival disease, existing ulcers, and other problems.⁶

STANDARD TREATMENT AND PREVENTION OF STOMATITIS

Stomatitis is still considered a nonpreventable side effect of chemotherapy. Only one drug – folic acid or calcium leucovorin, which was developed to protect normal cells against methotrexate – can help prevent the appearance of mucositis after methotrexate treatment.⁷ The current therapy for stomatitis, practicing extensive oral hygiene to slightly reduce the infections, is only symptomatic. In addition to performing oral hygiene with antiseptic alkaline mouthwash solutions, the local anesthetic drug Xylocaine™ is applied before brushing the teeth or before treating plaque and gingivitis, as well as an antifungal drug like nystatin. Such treatments are simply palliative, how-

ever, easing the severity and the accompanying side effects of the disease without curing it. The localized treatment is short lasting, the tastes of the drugs are extremely disagreeable, and the danger of absorption limits their frequency of application. Such treatment is effective only in mild-to-intermediate cases of stomatitis, at best, whereas intermediate and severe cases require systemic therapy with narcotics.² Indeed, in many cases, the developing stomatitis precludes the administration of planned chemotherapeutic agent regimens and decreases the planned aggressiveness and dosage of the administered drugs.

TRAUMEEL®

The information gained from reading anecdotal reports on the efficacy of standard treatments provided the rationale to perform a limited clinical trial to assess the feasibility of using the complex homeopathic preparation, Traumeel® for treating chemotherapy-induced stomatitis. Traumeel® Oral Liquid in Vials is a nonprescription drug developed in Germany, which has been sold for nearly a half-century in pharmacies in Germany, Austria, and Switzerland. Other dosage forms include oral drops, tablets, ointment, and ampules for injection.

Traumeel® Oral Liquid in Vials contains the following ingredients in 100 ml of isotonic saline: Arnica 2X, Calendula 2X, Millefolium 3X, Chamomilla 3X, Symphytum 6X, Belladonna 2X ana 0.1 ml, Aconitum 2X 0.06 ml, Bellis perennis 2X 0.05 ml, Hypericum 2X 0.03 ml, Echinacea angustifolia 2X, Echinacea purpurea 2X ana 0.025 ml, Hamamelis 1X 0.01, Mercurius sol. 6X 0.05 gr., and Hepar sulfuris 6X 0.1 gr. Trauma, inflammation, and degenerative processes are the main

indications for administering Traumeel®. The drug has no known toxic side effects (see below) because its ingredients are diluted by several orders of magnitude below toxic levels.

Veterinary uses of Traumeel®, such as in cattle that are destined for slaughter are also very popular in Germany. The slaughter of Traumeel®-treated cattle is not forbidden by German law. In German-speaking countries, Traumeel® is a very popular alternative drug and is used by many conventional physicians as well, especially in sports medicine. A 1981 manufacturer's survey of 3,300 German physicians showed that Traumeel® was prescribed for over 3.5 million patients, of whom 69% used the drug for up to 3 months. About 18% of the patients used it continuously for 3-6 months; 12% used it for over 6 months, and some patients used it for several years. Adverse side effects, such as skin reactions to the ointment or a local pruritus to the injections, were reported in only 0.0035% of the cases. Over 90% of the physicians using the drug expressed satisfaction with Traumeel®.

TOXICOLOGY OF TRAUMEEL®

Most of the ingredients of Traumeel® are either non-toxic or their toxicity is very low, due to their dilute concentrations. Because the concentration of each component in Traumeel® is almost zero, the likelihood of acute or chronic toxicology does not exist. Belladonna and Mercurius (mercury) are the two most toxic compounds in Traumeel®. In humans, the lethal dose of belladonna is 0.5-5 g/kg.¹⁰ More than 10 belladonna containing (tincture) drugs are on the market. For example, a 2.5% pediatric belladonna and ephedrine mixture contains belladonna tincture. The recommended dose for children (up to one year of age) is 0.5 ml.¹¹ Traumeel® Oral Liquid in Vials contains 0.001 ml of a stock solution of belladonna, meaning that one ampule containing 2.2 ml of a dilute solution contains 2.2 x 10⁻⁵ ml

belladonna 2X, which is 10⁻³ %. In other words, the belladonna concentration in a 2.5% pediatric belladonna and ephedrine mixture is about 1000 times higher than that in Traumeel®.

Traumeel® also contains the mercury compound Mercurius solubilis, with the following composition: Mercurio-amidonitrate (NH₂Hg₂NO₃), Mercurius metal, and Mercurius (1) oxide (Hg₂O). One ampule of Traumeel® contains 10⁻⁶ g Mercurius solubilis. In humans, the provisional tolerable weekly intake of mercury is up to 300 mg or 5 mg/kg.¹² A patient who needs 35 doses of Traumeel® per week would thus have a weekly intake of 3.5 x 10⁻⁵ g or a third of the allowable mercury content in drinking water according to German law.

CHEMOTHERAPEUTIC AGENTS COMMONLY ASSOCIATED WITH MUCOSITIS

Drug	Related factors
Methotrexate	May be quite severe with prolonged infusions or compromised renal function.
5-Fluorouracil	More severe with higher doses, frequent schedule, and arterial infusions.
Actinomycin D	Very common, may prevent oral alimentation. Severity enhanced by irradiation.
Doxorubicin (Adriamycin)	May be severe and ulcerative. Increased with liver disease. Severity enhanced by irradiation.
Bleomycin	May be severe and ulcerative.
Vinblastine	Frequently ulcerative.

(Peterson DE, Schubert MM. Principles of Oncology Nursing.)

Tab. 1: Chemotherapeutic Agents Commonly Associated with Mucositis

CLINICAL COURSE OF MUCOSITIS

Stomatitis can appear before the bone marrow becomes suppressed. The first symptoms of mucositis (inflammation of all mucosa) are expressed by stomatitis. The mucous membranes of the mouth are more sensitive than those of the intestine, possibly because of their different rates of cell division. Therefore, mouth ulcers may predict future damage to the entire alimentary canal. The development of mucositis in the small intestine or in other locations along the intestinal tract before expression in the oral cavity has been reported only rarely. Mucositis can be general, also invading the mucosa of the nose and conjunctiva.

The most common form of mucositis is stomatitis, in which the patient complains of a burning feeling, which begins about a week after the beginning of the treatment and is followed by the appearance of ulcers that coalesce. The lesions in the oral cavity

appear everywhere on the oral mucosa, including the tongue, gums, and lips. The ulcers cause constant pain that is exacerbated by eating, drinking, and swallowing. A cytological examination reveals epithelial hyperplasia, dysplasia, atropia, and degeneration of the glandular structure.

The Disease Staging of the World Health Organization (WHO) diagnosis for stomatitis is as follows:

Stage 0	no ulcers
Stage 1	oral pain with no ulcers
Stage 2	oral pain with ulcers but the ability to eat is retained
Stage 3	liquid diet only
Stage 4	inability to eat or to drink

MUCOSITIGENIC DRUGS AND THEIR MODE OF ACTION

Most experimental work on cytotoxic, mucositogenic drugs has been done using 5-fluorouracil and methotrexate. Both drugs inhibit DNA synthesis by inhibiting the synthesis of thymidylate, thereby preventing RNA and protein synthesis as well. After treatment with such drugs, the changes in the intestine resemble those of celiac sprue (gluten enteropathy), concentrating in the lining of the small intestine.⁷

AGE DISTRIBUTION OF PATIENTS ADMITTED TO TRAUMEEL® TRIAL*

Group	Number	Mean age (years)	Standard deviation age	Maximum (years)	Minimum age (years)
Treated	20	12.30	3.799	18	6
Untreated	7	11.29	3.302	16	7

*ANOVA, p=0.54

Tab. 2: Age Distribution of Patients Admitted to Traumeel® Trial

DISTRIBUTION OF DISEASE STAGE IN PATIENTS ADMITTED TO TRAUMEEL® TRIAL* • DISEASE STAGE

Group	1		2		3		4		Total
	No.	%	No.	%	No.	%	No.	%	
Treated	4	20.0	2	10	9	45.0	5	25	20
Untreated	2	28.6	0	0	3	42.0	2	28.6	7
Total	6		2		12		7		27

*Pearson Chi Square: Value = 0.902; D.F. = 3; prob. = 0.8249

Tab. 3: Distribution of Disease Stage in Patients Admitted to Traumeel® Trial

DISTRIBUTION OF PRE-TRIAL TREATMENT STATUS IN PATIENTS ADMITTED TO TRAUMEEL® TRIAL1 • ANTI-CANCER TREATMENT STATUS*

Group	Post-chemother.		GVHD		PBMT		PTBI		Total
	No.	%	No.	%	No.	%	No.	%	
Treated	11	55.0	2	10.0	6	30.0	1	5.0	20
Untreated	4	57.1	0	0.0	2	28.6	1	14.3	7
Total	15		2		8		2		27

*Pearson Chi Square: Value = 1.311; D.F. = 3; prob. = 0.7264 ¹GVHD: graft-versus-host disease; PBMT: post bone-marrow transplant; PTBI: post total body irradiation

Tab. 4: Distribution of Pre-Trial Treatment Status in Patients Admitted to Traumeel® Trial

DISTRIBUTION OF OPIATE REQUIREMENT IN PATIENTS ADMITTED TO TRAUMEEL® TRIAL* • OPIATE TREATMENT

Group	No		Yes		Total
	No.	%	No.	%	
Treated	18	90.0	2	10.0	20
Untreated	4	57.1	3	42.9	7
Total	22	100	5	100	27

*Fisher Exact Test (2-tail), p=0.09

Tab. 5: Distribution of Opiate Requirement in Patients Admitted to Traumeel® Trial

LIMITED CLINICAL TRIAL WITH TRAUMEEL® IN CHEMOTHERAPY-INDUCED STOMATITIS

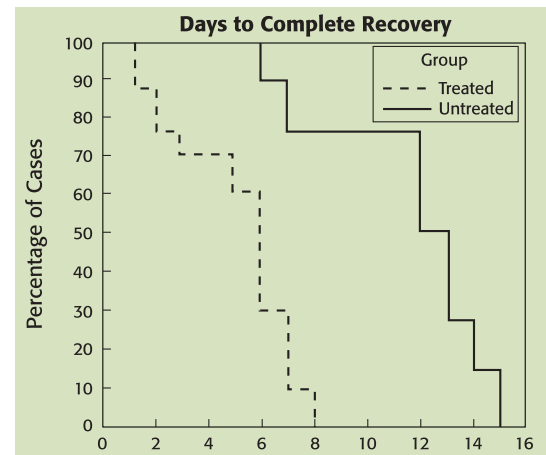
We studied 27 subjects between the ages of 6 and 18 years to evaluate the feasibility of using Traumeel® Oral Liquid in Vials for treating chemotherapy-induced stomatitis. Twenty patients received Traumeel® and seven children who did not receive Traumeel® were chosen at random for a prospective follow-up to compare the duration of symptoms in study participants to untreated stomatitis patients. We assessed the distribution of ulcer severity in all participants according to WHO staging.

The age distribution (Table 2), stages of disease (Table 3), and anticancer treatments (Table 4) were similar in both groups. In the untreated group, however, opiate use was higher, although the difference was not statistically significant (see Table 5). All statistical analyses were carried out using BMDP Statistical Software.¹³

In all treated children, each treatment was followed by an immediate decrease in pain, which continued for 30 minutes to 2 1/2 hours. In children with Stages 1-2 stomatitis, the pain reduction lasted between 24-72 hours until the stomatitis disappeared. Children that began with Stages 3-4 stomatitis required 6-8 days of treatment. In two children with GVHD (graft versus host disease)-associated stomatitis, the pain was significantly reduced for several hours, and then 24 hours later the children ceased to complain about pain. Nevertheless, the basic process that had caused the stomatitis in these two children continued, so the children continued to receive treatment 2-3 times per day for another 5-10 days. Only one participant, a patient with Stage 4 stomatitis, according to the WHO definition, was receiving morphine at the beginning of the trial. Immediately after the first dose of Traumeel®, the morphine dosage was reduced by half. No other participant required treatment with narcotics, and

those with Stages 1-2 stomatitis at the beginning of the trial no longer required analgesic treatment.

Table 6 shows the product-limit survival analysis that we used to compare symptom duration. From this table it can be seen that the difference between the two groups is highly significant, according to stringent statistical analysis. The median symptom duration in the treated group was 6 days, compared with 13 days in the untreated group.



Tab. 6: Days to Complete Recovery

CONCLUSION

We conducted this small preliminary study to gain a first impression about the effectiveness of Traumeel® Oral Liquid in Vials on mucositis. Obtaining positive results in such a study is a prerequisite to performing a large scale clinical trial according to strict scientific guidelines. Although we did not conduct this study as a randomized, double-blind trial, and the number of participants was small, the results were still impressive. Even if we presume that part of the success was due to the placebo effect, which is known to be very small in a hyper-acute system, such encouraging results led us to believe that Traumeel® Oral Liquid in Vials has genuine biological activity. In addition to its biological activity, the onset of action of Traumeel® was remarkable, with patients reporting a strong amelioration of pain within minutes. Some patients also reported a mood improvement. Such rapid

action is unusual because the mucosa does not regenerate within minutes. Notably, the improvement persisted. Although the decreased use of opiates as analgesics in the Traumeel®-treated group was not significant, we recognized a clear tendency toward such a decrease, so we speculate that the results of a study on a larger group of participants might show a difference in favor of the Traumeel®-treated patients. The results of this limited, preliminary trial support the feasibility of performing a prospective, double-blind trial to assess whether positive results will be obtained under more stringent, scientific conditions, and whether Traumeel® treatment can reduce the duration of pain in stomatitis patients. Such a study is currently taking place in two medical centers in Israel.

REFERENCES

- Raber-Durlacher JE, Abraham-Inpijn L, et al. The prevention of oral complications in bone marrow transplantation by means of oral hygiene and dental intervention. *Neth J Med.* 1989; 34:98-108.
- Johnson FT, Pochedly C (eds). *Bone Marrow Transplantation in Children.* Raven Press, New York, USA: 1990.
- Dreizen S, Brown LR. Oral microbial changes and infections during cancer chemotherapy. In: Peterson DE, Sonis ST (eds), *Oral Complications of Cancer Chemotherapy.* Iliglia, MA, Martinus Nijho F; 1983: 41-77.
- Dreizen S, McCreddie KB, Keating MJ, Bodey GP. Chemotherapy-associated oral infection in adults with acute leukemia. *Postgrad Med.* 1982; 71:133-46.
- Personal Communication from Dreizen S, Bodey GB, Valdinieso M. Cited in Peterson DE, *Toxicity of Chemotherapy, Oral Lesions,* In: Perry MC, Yarbrow JW (eds) *Toxicity of Chemotherapy.* Orlando FL: Grune & Stratton, 1984:166.
- Peterson DE, Sonis ST. Oral complications of cancer chemotherapy: Present status and future studies. *Cancer Treat Report.* 1982; 66:1251-56.
- Shaw MT, Spector MH, Ladman AJ. Effects of cancer radiotherapy and cytotoxic drugs on intestinal structure and function. *Cancer Treat Rev.* 1979; 6:141-51.
- Young DM. *Cancer Chemother Report (Part 3)* 1975; 6: 159, cited by Shaw MT, Spector MH, Ladman AJ. Effects of cancer radiotherapy and cytotoxic drugs on intestinal structure and function. *Cancer Treat Rev.* 1979; 6:141-51.
- Anon. *Handbook for reporting results of cancer treatment.* World Health Organization, Geneva, 1977; 48: 12-22.
- Gosselin, Smith, Hodge. *Clinical Toxicology of Commercial Products.* 5th Edition. Section II. loc no. 658.
- Martindale-The Extra Pharmacopoeia. 28th Edition. 1982: 293-294.
- ibid., p. 298; cited from the Sixteenth Report of FAO/WHO Expert Committee on Food Additives, Tech. Rep. Ser. Wld. Hlth. Org. No. 505 1972. See also Food Add. Ser. Wld. Hlth. Org. No. 4 1972. Twenty-second Report of Joint Tech. Rep. Ser. Wld. Hlth. Org. No. 631: 1978.
- Dixon WJ (ed). *BMDP Statistical Software.* Berkeley: University of California Press: 1990.

Address of the author: Menachem Oberbaum, M.D.
Shaare Zedek Medical Center
The Institute of Research on Complementary Medicine
Department of Pediatrics
Jerusalem Israel

TREATMENT OF OTITIS MEDIA/EXTERNA WITH A MODERN HOMEOPATHIC REMEDY

Dr. Rainer Gottwald and Michael Weiser
Publication in preparation



Summary

The efficacy and tolerability of TRAUMEEL EARDROPS/OTEEL/BHI PURE EARDROPS* was investigated in the treatment of 409 patients, suffering from otitis media or otitis externa. The preferred initially administered dosage of OTEEL was 3 monodose preparations daily (78%). Within a 5 day-treatment, 88% of the patients reported a significant improvement of their disease conditions. The total symptom score was reduced from 1.85 (baseline) to 0.35 (final visit). A success of the therapy, defined as a global investigator assessment of "very good", "good" or "satisfactory" was reported for 96% of the patients. The tolerability of the therapy was assessed as "very good" or "good" in at least 98% of the cases.

Otitis media, otitis externa, homeopathy, antihomotoxicology, cohort study, Oteel

*The name of this product varies internationally, but the formula remains the same. Alternatively, when this product is not available, the content of Traumeel ampules may be used for the same purpose.



EUPHORBIVM COMP. (CONTROLLED DOUBLE-BLIND STUDY OF A HOMEOPATHIC SINUSITIS MEDICATION)

Dr. M. Weiser and B.P.E. Clasen • Biological Therapy • Vol. XIII, No.1, 1995, pp. 4-11

Summary

Topic: Investigation of the clinical effectiveness of Euphorbium compositum S Nasal Spray in therapy of chronic sinusitis.

Design: Randomized, placebo controlled, double-blind study over a five-month period.

Subject / Collective: Included solely in this study were subjects who have suffered from established, chronically recurrent - although not acute - rhinosinusitis, for whom conservative therapy was indicated during symptom-free intervals. Excluded from this study, among others, were patients who smoked, suffered from nasoendoscopically confirmed polyposis or infectious rhinitis, who were known to possess unhealed apical granulomata, whose cases of sinusitis were established to be odontogenous, or who had undergone surgical treatment within the previous six months. The investigation encompassed a total of 172 patients, 155 of whom were included in the final evaluation (89.6%).

Intervention: 2 discharges of verum or placebo respectively into each nostril 4 times daily over a period of five months.

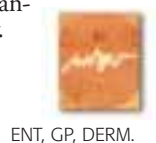
Chief Objective Variables: : For the purpose of statistical comparison among the therapeutic groups, a cumulative score was calculated from the data compiled in the three sectors "Subjective Symptoms ("day/night)", "Anterior Rhinoscopy", and "Ultrasound Examination of the Paranasal Sinus".

Results: Statistical comparison of the therapeutic collectives demonstrates significant superiority of Euphorbium compositum S Nasal Spray (5 % significance level, p = 0.016). Improvement was most evident within the subjective criteria of respiratory obstruction, sensation of pressure, and headache. Euphorbium compositum S Nasal Spray was well tolerated.

Conclusion: This study substantiates the reliable efficacy and good tolerance of Euphorbium compositum S Nasal Spray in therapy of chronic sinusitis. In addition, it demonstrates maintenance of a high standard of methods and acquirement of meaningful test results to indeed be feasible in homeopathy.



Euphorbium compositum S, chronic sinusitis, double-blind study



ENT, GP, DERM.