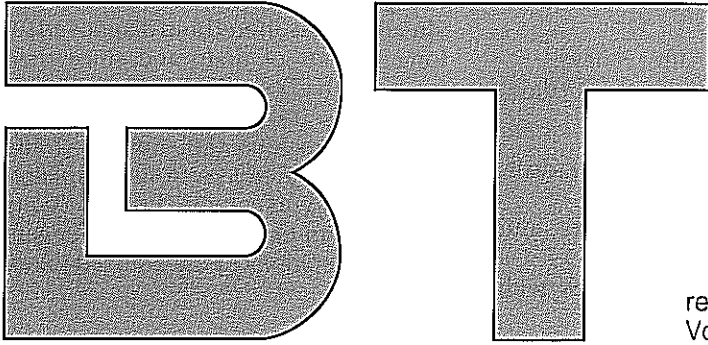


BIOLOGICAL THERAPY

JOURNAL OF NATURAL MEDICINE



reprinted from Biological Therapy,
Vol. XI No. 1, 1993, pp. 31-32

Biological Therapy of Rheumatic Pain in an Orthopedist's Practice

by Josef Fischer, M.D., Orthopedist

The concept involved in the term „rheumatism“ is phenomenologically oriented to a symptom of disease: pain. Typically indefinite pain in the vicinity of endangered points of the musculoskeletal system is the one characteristic common to all disorders included under the generic designation of rheumatism. The symptom pictures included under rheumatism are greatly varied in nature and encompass an extremely broad range: beginning with the many types of inflammatory articular diseases (arthritis), and extending to the so-called pararheumatic disorders. Rightly included among pararheumatic illnesses are also intestinal disorders such as colitis ulcerosa, as well as a great number of metabolic diseases which in a broad sense are related to the musculoskeletal system. In such cases, the pain in the musculoskeletal system is a symptom of a fundamental nonrheumatic illness [1].

The following list represents a very rudimentary schematic subdivision of disorders from the complex of rheumatic diseases:

1. Inflammatory disorders of the joints.
2. Degenerative joint disorders.
3. Extraarticular rheumatism (also known as soft-tissue rheumatism).
4. Pararheumatic diseases.

Until today, medical science has gained only insufficient insights into the etiological factors and pathogenetic processes involved in rheumatic disorders: this situation is, to a large extent, the result of the great variety and complexity of symptom pictures encountered. As a result, the development of therapeutic measures in this area has hardly proceeded past mere symptomatic treatment of rheumatic complaints. Although manufacturers have marketed a multitude of pharmaceutical products for rheumatism, they basically represent merely many variations on simple measures which suppress the symptoms of inflammation and pain.

These powerful preparations intervene into the system of prostaglandin acid

synthesis. Such therapy, however, also has powerful effects on other bodily functions: for example, blood coagulation and processes which protect gastric mucosa. In other words, medication of this nature has undesirable side effects.

The biologically effective preparation Zeel[®], made and marketed by the company Heel[®] Biotherapeutics of Baden-Baden, Germany, is based on another principle. The primary effects of this medicinal agent are not concentrated on symptomatic therapy. Treatment by Zeel[®] is instead based on the standpoint that biologically effective therapy of rheumatic disorders must include normalization of the disturbed metabolic processes, especially in the joint or in the vicinity of the joint. This therapy provides the organism with essential molecular components required for the development of new tissue structures. In addition to various active constituent complexes of plant origin, Zeel[®] also contains cartilage extract as well as substances associated with intermediate metabolism particu-

larly with cell respiration.

In the following, I would like to present a summary of my own therapy with seven patients, using the preparation Zeel®.

In all cases where possible, I employed Zeel® injection solution, with application by periarticular infiltration. In the two cases in which patients suffered from arthrosis of the wrist and of the saddle joint, I decided on account of the technical difficulties which might arise with injections to administer Zeel® in ointment form.

Patient 1: female, 29 years old.

Diagnosis: epicondylitis humeri radialis (left side).

Symptoms: pain upon pressure and movement.

Therapy: 2 infiltrations per week with Zeel® injection solution.

Relief from symptoms: after 3 infiltrations.

Freedom from complaints: after 8 infiltrations.

Patient 2: male, 63 years old.

Diagnosis: periarthrosis humeroscapularis.

Symptoms: pain upon pressure and movement.

Therapy: 2 infiltrations per week with Zeel® injection solution.

Relief from symptoms: after 4 infiltrations.

Freedom from complaints: after 6 infiltrations.

Patient 3: female, 48 years old.

Diagnosis: arthrosis of the wrist.

Symptoms: swelling; pain upon pressure and movement.

Therapy: rubbing in of Zeel® Ointment 3 times a day.

Relief from symptoms: after 4 days.

Freedom from complaints: after 18 days.

Patient 4: female, 36 years old.

Diagnosis: arthrosis of the saddle joint.

Symptoms: pain upon movement; swelling.

Therapy: rubbing in of Zeel® Ointment 3 times a day.

Relief from symptoms: after 3 days.

Freedom from complaints: after 15 days.

Patient 5: male, 42 years old.

Diagnosis: epicondylitis humeri radialis (right side).

Symptoms: pain upon pressure and movement.

Therapy: 2 infiltrations per week with Zeel® injection solution.

Relief from symptoms: after 2 therapy sessions.

Freedom from complaints: after a total of 4 infiltrations.

Patient 6: male, 43 years old.

Diagnosis: gonarthrosis, right side.

Symptoms: swelling of articular capsule.

Therapy: 2 infiltrations per week with Zeel® injection solution.

Relief from symptoms: after 1 infiltration.

Freedom from complaints: after 4 infiltrations.

Patient 7: female, 67 years old.

Diagnosis: gonarthrosis.

Symptoms: swelling of articular capsule; pain.

Therapy: 1 ampule of Zeel® injection solution, injected on each of 2 consecutive days.

Relief from symptoms: after the first infiltration.

Freedom from complaints: after the second infiltration.

In all cases, my patients showed excellent tolerance to the medication: a very important factor, especially in cases of inflamed and irritated joints. None of the patients suffered from side effects.

The complete freedom from complaints after very short treatment on the average, after about five infiltrations was especially impressive: particularly since the patients' arthritis complaints had already been suffered and diagnosed for long periods of time, and since their treatment had even included shortwave techniques. It is also interesting that for five of my patients (i.e., not nos. 1 and 5), complete freedom from complaints was achieved even though X-ray examination had earlier shown degenerative alterations of the afflicted joints.

Reference:

1. Kühn H.A., Schirmeister J.: Innere Medizin, 4th edition 1982: 303 ff. Springer Verlag publishers, Berlin and Heidelberg, Germany.

Address of the author:

Dr. Josef Fischer
Orthopedist
Osseckerstr. 1
D-95030 Hof/Saale
Germany